

CASE REPORT AND CLINICAL REVIEW

# Deep fungal dermatitis caused by the *Chrysosporium* anamorph of *Nannizziopsis vriesii* in captive coastal bearded dragons (*Pogona barbata*)

RSP Johnson,<sup>a,b\*</sup> CR Sangster,<sup>a</sup> L Sigler,<sup>c</sup> S Hambleton<sup>d</sup> and JA Paré<sup>e</sup>

Deep fungal dermatitis caused by the *Chrysosporium* anamorph of *Nannizziopsis vriesii* (CANV) was diagnosed in a group of coastal bearded dragons (*Pogona barbata*). The outbreak extended over a 6-month period, with four of six lizards from the same zoological outdoor enclosure succumbing to infection. A fifth case of dermatomycosis was identified in a pet lizard originally sourced from the wild. Diagnosis of infection with the CANV was based on similar clinical signs and histopathology in all animals and confirmed by culture and sequencing of the fungus from one animal. This is the first report of the CANV causing disease in a terrestrial reptile species in Australia and the first in the coastal bearded dragon.

**Keywords** *Chrysosporium* anamorph of *Nannizziopsis vriesii*; coastal bearded dragon; *Pogona barbata*; yellow fungus disease

**Abbreviation** CANV, *Chrysosporium* anamorph of *Nannizziopsis vriesii*

*Aust Vet J* 2011;89:515–519

doi: 10.1111/j.1751-0813.2011.00851.x

The *Chrysosporium* anamorph of *Nannizziopsis vriesii* (CANV) is a keratinophilic ascomycetous fungus<sup>1,2</sup> that causes contagious dermatomycosis in inland bearded dragons (*Pogona vitticeps*) in North America and Europe.<sup>3–6</sup> Skin infection slowly progresses to systemic and often fatal disease and the condition has been referred to as ‘yellow fungus disease’. In Australia, the CANV has been documented as a cause of severe and contagious dermatomycosis in farmed saltwater crocodiles (*Crocodylus porosus*)<sup>7</sup> and has been recovered from file snakes (*Acrochordus* sp.) with cutaneous lesions.<sup>2</sup> This is the first case of proven CANV infection in a terrestrial species native to Australia and is the first incidence in the coastal bearded dragon (*Pogona barbata*). All lizards except one were housed entirely outdoors. Previous reports of the CANV infection in reptiles involved animals housed indoors. This report also highlights the problems encountered with laboratory identification of the CANV and the clinical management of cases of mycotic dermatitis in reptile collections.

The coastal bearded dragon is native to Australia and the largest species in the *Pogona* genus, with a snout–vent length of 25 cm.<sup>8</sup>

\*Corresponding author.

<sup>a</sup>Taronga Wildlife Hospital, Taronga Zoo, Taronga Conservation Society Australia, Mosman, New South Wales 2088, Australia; [rjohnson@zoo.nsw.gov.au](mailto:rjohnson@zoo.nsw.gov.au)

<sup>b</sup>South Penrith Veterinary Clinic, Penrith, NSW, Australia

<sup>c</sup>University of Alberta Microfungus Collection, Devonian Botanic Garden, Edmonton, AB, Canada

<sup>d</sup>Biodiversity (Mycology and Botany), Eastern Cereal and Oilseed Research Centre, Agriculture and Agri-Food Canada, Ottawa, ON, Canada

<sup>e</sup>Global Health Programs, Wildlife Conservation Society, Bronx, NY, USA

Semi-arboreal in its habits, it is often seen during the day perched on fallen timber, stumps, fence posts or roadside verges foraging for insects. It also feeds on flowers and soft herbage. Distribution of the species is widespread over eastern and south-eastern Australia, excluding Cape York and Tasmania.<sup>8</sup>

## Case reports

### Cases 1–4

Four coastal bearded dragons housed in the same zoological outdoor enclosure initially presented to the Taronga Wildlife Hospital, Sydney, over a 2-month period in late winter and early spring (17/7/2008–10/9/2008) with crusty, ulcerative skin lesions affecting the head, body or limbs. All animals were euthanased within 6 months as a result of disease progression. Two other animals in the same enclosure did not develop clinical disease and were subsequently moved to a different location. The clinical signs and chronological course of the disease for this case series are summarised in Table 1. Specimens for histopathological examination were stained with haematoxylin–eosin and silver methenamine to highlight fungal organisms.

The enclosure was south facing and subject to outdoor weather conditions, with shelter provided by logs, rocks, tussocks of grass and an awning extending over part of the exhibit. The substrate consisted of sand, leaf mulch and grass. The winter weather leading up to presentation of the first case was particularly cold, wet and windy. The apparent (wind chill) temperature fell to  $-1^{\circ}\text{C}$  during this time, one of the few times the apparent temperature has fallen below freezing or  $0^{\circ}\text{C}$  in this coastal Australian region.<sup>9</sup>

A 208 g, adult male (case 1) presented with swelling and ulceration of a digit of the left hindlimb. The lizard was otherwise well. The affected digit was amputated under general anaesthesia and treatment commenced with itraconazole (Sporanox, Janssen-Cilag; 5 mg/kg PO once daily). Histopathology of the amputated digit revealed severe, multifocal, granulomatous dermatitis with intralesional fungi and bacteria. The lizard was euthanased 6 weeks later because of severe gingival recession and facial oedema. Histopathology of postmortem samples revealed necrotic skin lesions with hyphae similar to those seen in the biopsy of the amputated digit. In addition, granulomas consistent with fungal infection were seen in multiple internal organs and confirmed in a mesenteric nodule. Culture of the skin was unrewarding.

A 20-month-old, 134 g, female (case 2) presented with a superficial, crusty cheilitis affecting the upper and lower lips. The reptile was relocated in a heated vivarium for treatment. The condition was

**Table 1.** Details of cases 1–4 of deep fungal dermatitis in coastal bearded dragons from the same enclosure (31/07/2008–06/01/2009)

Case no.	Signalment	Clinical signs	Treatment	Date of onset of clinical signs	Date of death/euthanasia
1	Male, adult	Swelling and ulceration of the digit, gingival recession, facial oedema	Amputation of the digit, itraconazole	17/07/2008	09/09/2008
2	Female, 20 months	Cheilitis, crusting lesions to the mandibular skin, pathological fracture of the mandible	Topical treatment	02/09/2008	28/10/2008
3	Male, 18 months	Deep necrotic dermatitis of the mandible, gingival recession; crusting lesions to the tarsus, carpus, digits and cloaca	Debridement, topical treatment	10/09/2008	21/10/2008
4	Male, 24 months	Dermatitis of the mandibular skin, previous amputation of one limb, necrotic dermatitis of the stump and hindlimb digit, weight loss	Debridement and dressing of wounds, topical treatment	10/09/2008	06/01/2009

treated with a topical combination triamcinolone acetonide, neomycin, thiostrepton, nystatin ointment (Panalog, Novartis) once daily and resolved after 1 month. Follow-up examination 7 weeks later revealed multiple crusty nodular lesions of the rostral mandibular skin extending to the underlying bone, resulting in a pathological fracture and non-union of the symphysis. The lizard was euthanased. Histopathological examination revealed severe ulcerative and granulomatous dermatitis with intralesional hyphae and severe, multifocal to coalescing, granulomatous hepatitis with intralesional hyphae. Fungal culture grew an isolate initially identified as *Trichophyton tonsurans*; however, the isolate was not saved for follow-up investigation.

An 18-month-old, 252 g, male (case 3) presented with a deep, necrotic dermatitis of the rostral mandible and marked gingival recession. Two months previously, a superficial crusty lesion of the cranial cloacal mucosa had been treated topically with an ophthalmic antibiotic ointment (Opticin, Ilium). The lizard was rehoused in a thermostatically-controlled, heated vivarium. Necrotic and crusty material was debrided from the rostral mandible and triamcinolone acetonide, neomycin, thiostrepton, nystatin ointment (Panalog, Novartis) was applied to the underlying tissue once daily for 14 days. The lizard was bright and responsive but thin. After initial improvement, the mandibular skin lesion became swollen and reddened in appearance. Five weeks after presentation with the mandibular lesions, the lizard was examined under general anaesthesia. The skin lesions were debrided, and samples of affected tissue were submitted for culture while systemic antibiotic therapy was commenced. The lesion was also treated topically with 10% povidone iodine solution. Examination 3 days later revealed a deep, ulcerative and painful to touch lesion (10 × 20 mm) on the rostral mandible and additional skin lesions on the right tarsal region, left carpus, digits and the cloaca. The lizard was euthanased. Histopathological examination revealed the presence of granulomatous dermatitis with intralesional hyphae that were morphologically identical to those seen in the two previous cases. Culture from an antemortem submission yielded a fungus similar to the previous isolate and identified also as *T. tonsurans* as in case 2.

A 2-year-old, 196 g, male (case 4) presented with a history of dental disease, dermatitis of the mandibular skin, and mid-humeral amputation of the left forelimb as the result of necrosis of the distal limb. The dermatitis had been treated previously but had recurred. Examination revealed a deep necrotic dermatitis of the right rostral mandible, as well as of the plantar aspect of the third digit of the right hindlimb and of the stump of the left forelimb. The lizard was thin, having lost 60 g in body weight over the previous 4 months. Anaesthesia was induced to enable surgical debridement of the skin lesions and irrigation with povidone iodine solution. The lesion on the left forelimb stump was dressed with cadexomer iodine (Iodosorb Ointment, Smith and Nephew) and bandaged (Allevyn Thin, Smith and Nephew; Fixomull Stretch, BSN medical GmbH). Cadexomer ointment was also applied to the mandibular lesion. The lizard deteriorated rapidly over the next 24 h and was euthanased. Histopathological findings consisted of a granulomatous, multifocal, chronic and severe dermatitis with intralesional hyphae. Heavy growth of a fungus identified as *Chrysosporium* sp. was cultured from the skin and the liver. Severe, multifocal, granulomatous, myocarditis and hepatitis with intralesional fungal elements were present.

#### Case 5

An adult, 248 g, male coastal bearded dragon was presented to South Penrith Veterinary Clinic with a crusty skin lesion over the left mandible. The lizard was originally wild caught and had been kept both outdoors in an aviary and indoors in a glass tank decorated with naturalistic cage furniture including bush rock, a 'mock rock' hide and leaf mulch as a substrate. A suboptimal diet of banana, meat and occasional crickets was fed. Supplementary heating and ultraviolet light were not provided. The temperature and humidity range within the enclosure were not recorded. The owner claimed that the skin lesion was present when the lizard was caught from the wild approximately 4 months before initial presentation. The lizard had gradually become lethargic and anorexic and the skin lesion was increasing in size. A swab of the lesion was submitted to a private laboratory for bacterial and fungal culture. The lizard was treated empirically with

enrofloxacin (Baytril, Bayer; 5 mg/kg SC 48 hourly) and topical 10% povidone iodine. Fungal culture yielded a *Candida* species. Adjustments to the husbandry were recommended, including provision of a radiant heat source and a cleaner substrate, preferably paper. Topical treatment of the skin lesion was commenced. For economic reasons the client declined further diagnostics and treatment. Three months after the initial visit the lizard was presented again for assessment. Physical examination revealed extensive ulceration and exposure of the bone of the maxilla, and ulceration of the left mandible (Figure 1). The owner elected to euthanase the lizard. It was submitted to the Taronga Wildlife Hospital for necropsy. Histopathological examination revealed moderate to severe, multifocal, ulcerative and granulomatous dermatitis (Figures 2, 3), rhinitis and conjunctivitis with intralesional hyphae. A fungus identified as *Chrysosporium* sp. was cultured from the skin specimen. The isolate was referred for identification to the University of Alberta Microfungus Collection and

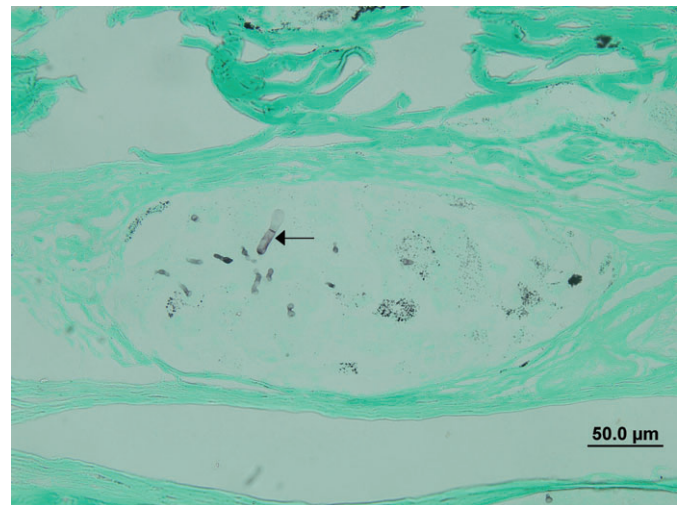
Herbarium (UAMH), Edmonton, Alberta, Canada. The isolate was confirmed as the CANV on the basis of morphology showing powdery yellowish-white colonies (Figure 4) and pyriform to cylindrical conidia borne on the sides of branched hyphae (Figure 5) and sequencing of the internal transcribed spacer (ITS) region of the ribosomal RNA gene (GenBank number JF323871).

### Discussion

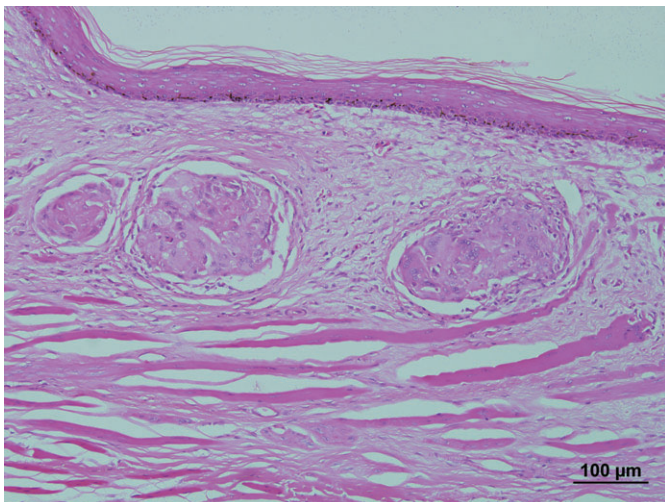
This report is the first describing deep fungal dermatitis with the CANV in the coastal bearded dragon. The infection has not previously been reported in reptiles housed outdoors or in terrestrial reptiles in Australia. Definitive diagnosis of the CANV infection was based on similar clinical presentations, histopathological evidence of



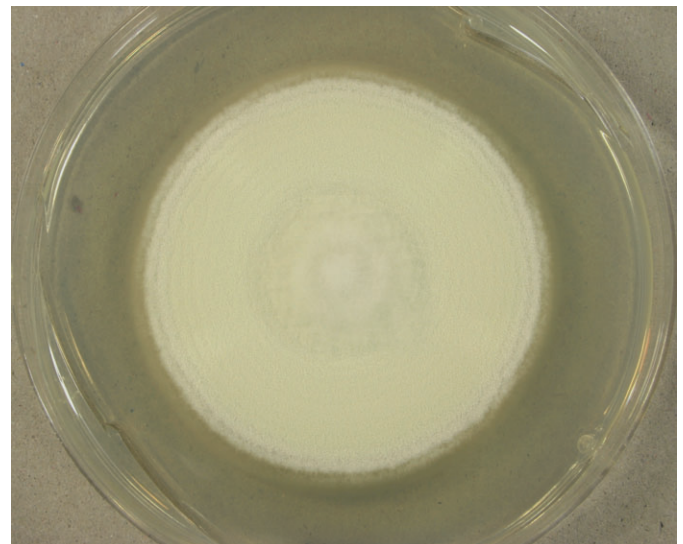
**Figure 1.** Coastal bearded dragon (case 5) showing extensive ulceration of the skin and exposure of the bone of the maxilla and mandible.



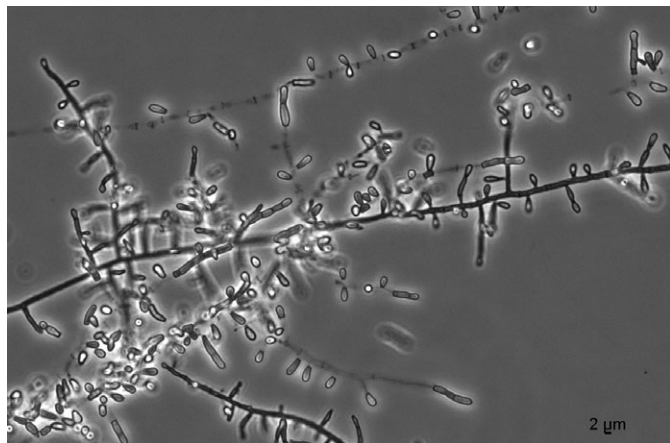
**Figure 3.** Histological section of the skin stained with silver methenamine to highlight fungal organisms (arrow).



**Figure 2.** Histological section of the skin stained with haematoxylin and eosin showing granulomatous dermatitis with intralesional hyphae.



**Figure 4.** Colony from case 5 isolate on potato dextrose agar after 21 days incubation at 30°C.



**Figure 5.** Microscopic morphology of case 5 isolate showing conidia borne on the sides of the hyphae.

intralesional hyphae, culture and ITS sequencing of the fungus in one case. Treatment of the dermatitis was undertaken in all cases, but proved ineffective.

Unlike most fungi that infect reptiles, the CANV is a primary pathogen and contagious in nature.<sup>10</sup> Studies have shown that the infection may progress rapidly once a breach in the skin occurs,<sup>10</sup> so it would be reasonable to assume that pre-existing skin lesions or wounds may have led to infection with the CANV. The presence of pre-existing skin wounds, possibly the result of intraspecific aggression among the group lizards and a chronic superficial skin lesion on the head of the pet lizard (case 5), may have provided an entry port for infection with the organism. It has been proposed, but not yet proven, that a carrier state may exist in some reptiles.<sup>4</sup>

Suboptimal husbandry and poor nutrition have been described as contributing factors in the CANV disease process.<sup>10</sup> In our cases, four animals were housed together in an outdoor exhibit and the fifth also spent time in an outdoor aviary. The CANV has not previously been recorded in terrestrial reptiles housed outdoors. The husbandry of the group lizards appeared adequate; however, the outbreak could have been exacerbated by unfavourable weather conditions. These lizards developed clinical signs within a 2-month period over late winter and early spring in a year that was particularly cold. Once it was determined that an outbreak had occurred, all the lizards were housed indoors. No further cases developed. Two lizards from the same enclosure were not affected. The provision of an enclosed heated indoor environment kept within the reptile's preferred optimal temperature zone often is sufficient to mount a positive immune response.<sup>11</sup> The preferred optimal temperature zone of the coastal bearded dragon has not been described in the literature. Given its wide distribution along the eastern coast of Australia, the species appears to tolerate a broad range in environmental temperature and humidity. Preferred body temperatures of coastal bearded dragons have been measured in a laboratory thermal gradient at 35.7°C.<sup>12</sup> The care of the pet lizard (case 5) was suboptimal in that neither supplementary heating nor access to ultraviolet light was provided for the lizard either indoors or outdoors and an inappropriate diet was fed.

Culture and identification of the fungus can be difficult. Historically, the CANV has been repeatedly confused with the morphologically

similar fungus *Trichophyton* sp.<sup>1,2,4</sup> A case of progressive digital necrosis in a captive-reared blue tongued skink, *Tiliqua scincoides*, similarly was attributed to *Trichophyton terrestre* infection,<sup>13</sup> but very likely represents a prior case of CANV infection in Australia. In most cases, it is not possible to evaluate the identifications because fungal isolates are seldom retained in culture collections for later re-examination. In cases 2 and 3, the diagnosis was hampered by the initial identification of *T. tonsurans*. Culture of case 4 yielded heavy growth of *Chrysosporium* but only the isolate from case 5 was saved for follow-up sequencing. In the latter case, another organism, *Candida* sp., was initially grown before the CANV was recovered later from the same lesion. It is possible that the lizard was infected at a later stage, but more likely that the CANV was present when the lizard was initially examined but not detected by culture.

Treatment was attempted in all cases described in this report, but proved ineffective. Treatment regimes have been described in the literature using long-term itraconazole therapy, at a dose of 5–10 mg/kg PO once daily, combined with surgical debridement or amputation.<sup>4</sup> Regular monitoring of biochemical analytes should be conducted to identify early signs of hepatotoxicity.<sup>4</sup> Pulse therapy has also been recommended in order to reduce further the risk of liver damage.<sup>14</sup> Voriconazole and terbinafine have been identified as possible alternatives to itraconazole in the treatment of yellow fungus disease.<sup>14–16</sup> Earlier diagnosis and implementation of a systemic treatment plan for the group lizards could potentially have limited the spread of disease and might have resulted in successful resolution of lesions. Topical corticosteroids administered in two cases might have influenced the progression of lesions, but the effects of systemic and/or topical corticosteroids on the immune system of reptiles are largely unknown. In addition, in the case of the pet lizard, diagnosis and treatment were hampered by financial and temporal constraints. Therapy of the CANV infection is often made difficult by the systemic nature of the disease, the extent of which may be difficult to assess antemortem. As this is the first described outbreak of the CANV in reptiles in an outdoor enclosure, there is little information available on the control of the disease outdoors. In this case, the enclosure was depopulated for 2 months and the substrate replaced; however, the large rocks and logs were retained but cleaned with a surface disinfectant (Virkon®, DuPont). There have been no further outbreaks, although bearded dragons are no longer kept in this enclosure.

The CANV is an emerging cause of disease in reptiles and more specifically in *Pogona* species. Molecular data reveals the existence of several subgroups within the CANV that are allied to specific reptile hosts (L Sigler and S Hambleton, unpubl. data). As species within the CANV complex become more precisely defined, it will be possible to gain a better understanding of the relationship between the pathogens and the diseases they cause. Research is needed also to determine the prevalence of the fungus in the environment, to ascertain the number of susceptible reptile species and to investigate suitable strategies in the prevention and treatment of yellow fungus disease in reptiles.<sup>10,17</sup> It is also imperative that surveys are carried out to determine the prevalence and significance of the CANV in both captive and free-living reptiles in Australia. Veterinarians treating reptiles in Australia should be aware of the CANV when formulating a differential diagnosis for ulcerative skin disease in bearded dragons and other reptile species. There is also need for improvement in the capability of

Australian veterinary laboratories to diagnose the fungus. Isolates having features suggestive of the CANV, as described here, should be retained for specialist identification. With respect to case 5, it should be emphasised that it is illegal under New South Wales law to catch protected wildlife and keep them as pets.

### Acknowledgments

The authors acknowledge the assistance of the clinical veterinarians at Taronga Wildlife Hospital in the treatment of cases and Kaye Humphreys for isolation of the organism. L Sigler thanks the Natural Sciences and Engineering Research Council of Canada for financial support.

### References

1. Paré JA, Sigler L, Hunter DB et al. Cutaneous mycoses in chameleons caused by the *Chrysosporium* anamorph of *Nannizziopsis vriesii* (Alpinis) Currah. *J Zoo Wildl Med* 1997;28:443–453.
2. Paré JA, Jacobson ER. Mycotic diseases of reptiles. In: Jacobson ER, editor. *Infectious diseases and pathology of reptiles*. CRC Press, Boca Raton, 2007;527–547.
3. Mitchell MA, Diaz-Figueroa O, Bernstein J et al. *Chrysosporium* anamorph of *Nannizziopsis vriesii* dermatitis in a bearded dragon (*Pogona vitticeps*). In: Baer CK, editor. *Proceedings of the Association of Reptile and Amphibian Veterinarians*. ARAV, Baltimore, MD, 2006;37.
4. Bowman MR, Paré JA, Sigler L et al. Deep fungal dermatitis in three inland bearded dragons (*Pogona vitticeps*) caused by the *Chrysosporium* anamorph of *Nannizziopsis vriesii*. *Med Mycol* 2007;45:371–376.
5. Abarca ML, Martorell J, Castellá G, Ramis A, Cabañes FJ. Dermatocycosis in a pet inland bearded dragon (*Pogona vitticeps*) caused by a *Chrysosporium* species related to *Nannizziopsis vriesii*. *Vet Dermatol* 2009;20:295–299.
6. Hedley J, Eatwell K, Hume L. Necrotising fungal dermatitis in a group of bearded dragons (*Pogona vitticeps*). *Vet Rec* 2010;166:464–465.
7. Thomas AD, Sigler L, Peucker S, Norton JH, Nielan A. *Chrysosporium* anamorph of *Nannizziopsis vriesii* associated with fatal cutaneous mycoses in the saltwater crocodile (*Crocodylus porosus*). *Med Mycol* 2002;40:143–151.
8. Cogger HG. Agamidae (Dragon lizards). In: Cogger HG, editor. *Reptiles and amphibians of Australia*. 6th edn. Reed New Holland, Frenchs Forest, 2000;298–355.
9. The Bureau of Meteorology. Monthly climate summary for Sydney, July 2008. <http://www.bom.gov.au/climate/current/month/nsw/archive/200807.sydney.shtml>. Accessed June 2010.
10. Paré JA, Coyle KA, Sigler L, Maas III AK, Mitchell RL. Pathogenicity of the *Chrysosporium* anamorph of *Nannizziopsis vriesii* for veiled chameleons (*Chamaeleo calyptratus*). *Med Mycol* 2006;44:25–31.
11. Guillette LJ, Cree A, Rooney AA. Biology of stress: interactions with reproduction, immunology and intermediary metabolism. In: Warwick C, Frye FL, Murphy JB, editors. *Health and welfare of captive reptiles*. Chapman & Hall, London, 1995;32–81.
12. Licht P, Dawson WR, Shoemaker VH, Main A. Observations on the thermal relations of Western Australian lizards. *Copeia* 1966;1:97–110.
13. Hazell SL, Eamens GJ. Progressive digital necrosis in the Eastern blue-tongued skink, *Tiliquascincoides* (Shaw). *J Wildl Dis* 1985;21:186–188.
14. Paré JA, Andes DR, Sigler L. In vitro susceptibility of fungal isolates from reptiles to antifungal drugs. In: Baer CK, editor. *Proceedings of the Group Joint Conference of the American Association of Zoo Veterinarians Annual Meeting*. AAZV, Omaha, NB, 2005;124.
15. Hellebuyck T, Baert K, Pasmans F et al. Cutaneous hyalohyphomycosis in a girdled lizard (*Cordylus giganteus*) caused by the *Chrysosporium* anamorph of *Nannizziopsis vriesii* and successful treatment with voriconazole. *Vet Dermatol* 2010;21:429–433.
16. Van Waeyenberghe L, Baert K, Pasmans F et al. Voriconazole, a safe alternative for treating infections caused by the *Chrysosporium* anamorph of *Nannizziopsis vriesii* in bearded dragons (*Pogona vitticeps*). *Med Mycol* 2010;48:880–885.
17. Paré JA, Sigler L, Rypien KL, Gibas CF. Cutaneous mycobiota of captive squamate reptiles with notes on the scarcity of *Chrysosporium* anamorph of *Nannizziopsis vriesii*. *J Herp Med Surg* 2003;13:10–15.

(Accepted for publication 31 May 2011)